REVIEW

Apert Syndrome: Revisited

Tibin K. Baby[1], Lisa Elizabeth Jacob[2], Anju Mathew[3], Nirupa Thomas[4], Lekshmi Venugopal[5]

Abstract

Introduction: Apert syndrome, also called acrocephalosyndactyly, is a genetic syndrome characterized by malformation of the skull, face and limbs. The typical syndactyly of Apert syndrome distinguish it from other craniosynostosis. The fibroblast growth factor receptor 2 (FGFR2) gene undergoes point mutation which causes the syndrome in 98% of the patients.

Clinical presentation and diagnosis: Apert syndrome is diagnosed with classic clinical characteristics (multisuture craniosynostosis, midface retrusion, and syndactyly), molecular genetic confirmation can be done by the identification of a heterozygous pathogenic variant in FGFR2.

Management and prognosis: Though there is no cure for Apert syndrome, many modalities can be done to prevent or treat complications, helping the child to grow better as possible.

Key words: Apert syndrome, Craniosynostosis, Acrocephalosyndactyly, Syndactyly, Synonychia, Fibroblast Growth Factor Receptor 2

Oral and Maxillofacial Pathology Journal (2021): ***https://www.ompj.org/archives.***

Introduction

Apert Syndrome/ Acrocephalosyndactyly is a genetic defect and falls under the broad classification of craniofacial/limb anomalies. Apert syndrome is named after the French physician who first described it, Eugen Apert in 1906.[1,2] Apert syndrome is mainly characterized by specific malformations of the skull, midface, hands, and feet. (Figs. 1&2) Apert syndrome both has craniosynostosis and syndactyly. Craniosynostosis means the skull is prematurely fused which causes undergrowth therefore the midface appears sunken. The fingers and toes are fused together in varying degrees which is known as syndactyly. (Figs. 1A&B) The incidence of Apert's syndrome is about 15 per 1,000,000 live births.[3] Apert Syndrome is rarely reported from India.[4]

Pathogenesis

Apert syndrome inherited with point mutations of either Ser252Trp or Pro253Arg in fibroblast growth factor receptor 2 (FGFR2) on chromosome 10q25. FGFR2 belongs to a complex system of intracellular signalling consisting of multiple fibroblast growth factors (FGFs) and their receptors FGFRs. This signalling network functions in the control of cell proliferation, differentiation, migration. The FGFR2 is active at the metaphysis; diaphysis and also in the interdigital mesenchyme. Mutations in the FGFR2 gene cause prolonged signalling, which can promote the premature fusion of bones in the skull, hands, and feet.[5-7]

Clinical features

The U.S. National Library of Medicine estimate that it affects 1 in 65,000 to 88,000 newborns, and the National Organization for Rare Disorders (NORD) estimate that the figure is closer to 1 in 165,000 to 200,000 births. Males and females can be affected equally.[8]

[1]Department of Oral Pathology, Pushpagiri college of Dental Science, Tiruvalla, Kerala; [2,3]Department of Oral Medicine, Pushpagiri college of Dental Science, Tiruvalla, Kerala; [4,5.] Department of Oral Pathology, Annoor Dental College, Muvattupuzha, Kerala.

Corresponding author: Tibin K. Baby, Department of Oral Pathology, Pushpagiri college of Dental Science, Tiruvalla, Kerala, Email Id: tibinkbaby@gmail.com

How to cite this article: Baby TK, Jacob LE, Mathew A, Thomas N,Venugopal L. Apert syndrome: Revisited. Oral Maxillofac Pathol J 2021; 12(2): 59-62

Source of Support: Nil

Conflict of Interest: None

Craniosynostosis: It is a near-universal finding in individuals with Apert syndrome, though some affected individuals with other typical manifestations (e.g., midface retrusion and syndactyly) without craniosynostosis have been reported. Most infants with Apert syndrome are born with fusion of one or more cranial sutures, though progressive craniosynostosis of other sutures can occur. The only possibility is that premature closure of cranial sutures, increased cranial pressure and can limits the growth of the brain and hence the intelligence. Depending on the involved sutures, most children with Apert syndrome have a large anterior fontanelle, which is displaced anteriorly onto the forehead.[9]

Midface retrusion. Unlike Crouzon syndrome in which the midface is well developed but retruded, Apert syndrome shows retruding midface with underdevelopment. (Figs. 2A&B) There is a greater degree of vertical impaction leading to a shorter

maxillary bone, with greater similarity to Pfeiffer syndrome than to Crouzon syndrome. The underdevelopment of the midface contributes to the development of shallow orbits and downslanting palpebral fissures. (Fig. 1C) Underdeveloped maxillary structures result in malocclusion and the appearance of relative mandibular prognathism.[10] (Fig. 2C)

Palatal abnormalities. Highly arched palate or cleft palate may occur. Cleft palate is frequently present in Apert syndrome which causes feeding problem, but rarely found in Crouzon syndrome.[9]

Dental abnormalities. Dental anomalies are common with Apert syndrome that require management by orthodontics and/or oromaxillofacial surgery. Tooth agenesis (typically of maxillary canines) and enamel opacities occur in more than 40% of children with Apert syndrome. Ectopic eruption of maxillary first molars and lateral palatal swellings are also common. (Fig. 2D) Other orthodontic differences include delayed dental eruption, missing teeth, dental crowding, and abnormal occlusal relationships. (Fig. 2C) Abnormalities of primary and adult teeth can be present.[11,12]

Ocular abnormalities. Apert syndromic children have prominent eyes showing proptosis with downslanting palpebral fissures. (Fig. 1C) The prominent eyes are typically due to bicoronal craniosynostosis and underdeveloped maxilla. Other primary ophthalmologic abnormalities include trabismus (60%), Refractive error (34%), Anisometropia (19%). Secondary ophthalmologic findings include exposure keratopathy and corneal scarring (8%) and optic atrophy (8%). These secondary findings may be preventable with aggressive surveillance and treatment of incomplete lid closure and increased intracranial pressure.[13]

Hearing loss/inner ear anomalies. Hearing loss is common (80%) and is typically conductive, caused by middle ear disease, ossicular abnormalities, and external auditory canal stenosis or atresia.[14]

Multilevel airway obstruction. Individuals with Apert syndrome may have abnormalities at multiple sites. Narrowing of the nasal passages or choanae can lead to upper-airway obstruction, and may contribute to respiratory distress as well as feeding difficulties. Tongue-based airway obstruction may also occur. Tracheal anomalies, including fused rings and tracheal cartilaginous sleeves, have been reported in a number of individuals.[9,15,16]

Syndactyly. The hands in Apert syndrome always show fusion of the middle three digits with or without involvement of the thumb and fifth finger. The fingernail for digits 2-4 is typically fused to form a single nail (synonychia). (Fig. 1A) The hands of Apert syndrome patients show three types; type I- spade, type II -mitten and type III rose bud.[17] Syndactyly of the toes may involve the lateral three digits, digits 2-5, or all digits. (Fig. 1B) In general, the upper limb is more severely affected than the lower limb. Synonychia has not been reported in the toes.[10]

Other limb anomalies that occur less frequently in individuals with Apert syndrome include synostosis of the radius and humerus, preaxial and/or postaxial polydactyly of the hands and/or feet, broad distal phalanx of the thumb or broad distal hallux.[10,18]

Spinal fusions. Cervical vertebral fusions are found in 68% of individuals with Apert syndrome, most commonly involving C5-C6. Of those with fusions, approximately 50% have a single fusion and 50% have multiple fusions. The prevalence and location of vertebral fusions differs from Crouzon syndrome, in which only 25% have vertebral fusion, most commonly involving C2-C3. Other cervical spine anomalies include atlanto-axial subluxation (7%) and C1 spina bifida occulta (7%).[19]

Progressive synostosis. Progressive fusion of several bones may occur, including bones of the skull, hands, feet, carpus, tarsus, and cervical vertebrae. Restriction of movement involving the shoulder due to glenohumeral dysplasia can lead to functional impairment. Children with Apert syndrome may experience progressive deformities of the foot leading to pain and difficulty with gait.[20]

Vascular and neurologic defects: Jugular foraminal stenosis is seen in 93% of affected individuals. Approximately 60% of individuals with Apert syndrome have nonprogressive ventriculomegaly

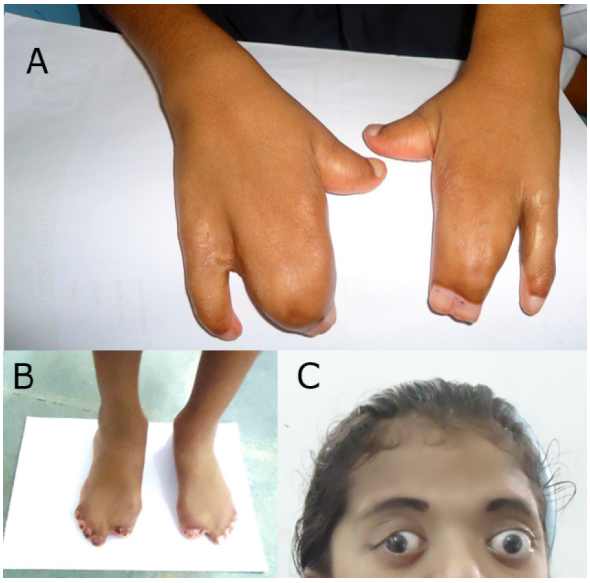

Fig. 1: Apert syndrome A. Syndactyly with synonychia B. Syndactyly C. Proptosis with downslanting palpebral fissures.

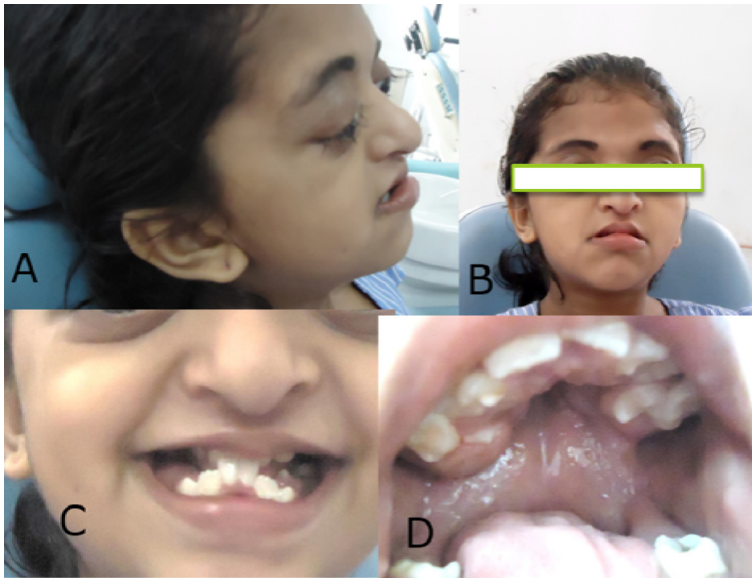

Fig. 2: Apert syndrome A and B Midface retrusion and relative mandibular prognathism. C. Dental crowding, and abnormal occlusal relationship D. Lateral palatal swellings.

and 6%-13% have hydrocephalus. Structural brain malformations in Apert syndrome include the following Abnormalities of the corpus callosum (23%). Absent septum pellucidum (17%). Chiari I malformation and/or low-lying cerebellar tonsils (17%). Posterior fossa arachnoid cyst (7%). Limbic malformations.[3,21]

Neurodevelopment. Most individuals with Apert syndrome have normal intellect or mild intellectual disability, though some individuals have been reported with moderate-to-severe intellectual disability Not surprisingly, children with Apert syndrome raised within the family have better cognitive outcomes than children who were institutionalized.[22,23]

Cardiovascular. Approximately 10% of individuals with Apert syndrome have structural cardiac abnormalities include ventricular septal defect and overriding aorta. Children with complex congenital heart disease are at greater risk for early death compared to children with structurally normal hearts.[5]

Gastrointestinal issues. Feeding difficulties can occur in Apert syndrome for a variety of reasons, and may require placement of a nasogastric or gastric tube. Gastrointestinal malformations reported in Apert syndrome include Distal esophageal stenosis, Pyloric stenosis, Esophageal atresia, Ectopic anus.[24]

Genitourinary. Anomalies of the genitourinary tract are identified in 9.6% of children with Apert syndrome, most commonly hydronephrosis or cryptorchidism.[5]

Skin changes. Hyperhidrosis is a consistent feature of Apert syndrome. The adulthood typically show oily skin in adolescence and extensive acneiform lesions on the face, chest, back, and upper arms. Some affected individuals develop excessive skin wrinkling of the forehead.[10] Nail dystrophy is also common.[25]

Adults. Adults with Apert syndrome appear to have more challenges with social development and relationships compared to unaffected controls and individuals with Crouzon syndrome.[26]

Diagnosis

Evaluation of Apert syndrome is a clinical one as the characteristic physical examination findings confirm the diagnosis. Apert syndrome is diagnosed with classic clinical characteristics of multisuture craniosynostosis, midface retrusion, and syndactyly. In cases where the clinical presentation is not clear and no family history to support the diagnosis, additional tests such as magnetic resonance imaging (MRI) and computed tomographic (CT) imaging of the brain are used to detect craniosynostosis or other skeletal abnormalities.[9,27] Molecular genetic confirmation can be done by the identification of a heterozygous pathogenic variant in FGFR2 by Sequence analysis or Gene-targeted deletion/duplication analysis. Prenatal genetic testing, MRI, and ultrasounds can be utilized to confirm the diagnosis before the birth of the child.[18,27]

Treatment

Apert syndrome has no known cure. Correction of abnormal connections between bones is the main treatment for Apert syndrome. Surgery for Apert syndrome takes place in three steps: 1. Release of skull bone fusion (craniosynostosis release). Usually performed when a child is between ages 6 and 8 months. 2. Midface advancement which is done between ages 4 and 12. 3. Correction of wide-set eyes (hypertelorism correction). Surgery is done to remove a wedge of bone in the skull between the eyes.[28,29] Other Apert syndrome treatments include: Eyedrops during the day, with lubricating eye ointment at night; these drops can prevent the dangerous eye drying that can occur in Apert syndrome. Surgical placement of ear tubes (myringotomy), for children with repeated ear infections due to Apert syndrome. [28,29]

Prognosis

Apertic children require surgery for release of the skull bones so that the brain to develop normally. The younger a child is to undergo surgery, better to reach normal intellectual ability. Life expectancy also varies between children with Apert syndrome. Those with Apert syndrome who survive past childhood and don't have heart problems likely have a normal or near-normal life expectancy.[2,5]

Complications

The complications with Apert syndrome include: Increased intracranial pressure that can cause papilledema and cognitive impairment,exposure keratopathy and corneal scarring, respiratory complications like aspiration pneumonia and further chronic lung disease., Spinal cord injury and neurologic deficits in patients with cervical spine anomalies. [2]

Differential Diagnosis

Apert syndrome shows substantial overlap with other FGFR2-associated craniosynostosis syndromes. Apert syndrome can be readily distinguished from other syndromic craniosynostosis syndromes (e.g., Crouzon, Pfeiffer, Jackson-Weiss, Beare-Stevenson) at or before birth due to the presence of syndactyly.[2] Apert syndrome resembles with Crouzon syndrome the most. In the Crouzon syndrome, extremities are not involved and craniofacial deformities lead a milder course unlike Apert syndrome. Hand, and foot deformations, and especially extreme cases of syndactyly is its discriminative feature for Apert syndrome. Unlike Pfeiffer syndrome, Apert syndrome presents with Chiari 1 malformation more commonly, broad & deviated thumbs & great toes as well as brachydactyly. Apert syndrome can be differentiated from Jackson-Weiss syndrome as there is no fusion of tarsal & metatarsal bones, 2-3 syndactyly, broad & medially deviated great toes, short 1st metatarsals and broad proximal phalanges only seen in Apert syndrome.[2,13,23]

Genetic counseling

Apert syndrome has an autosomal dominant manner of inheritance. Most individuals with Apert syndrome have the disorder as the result of a de novo FGFR2 mutation. Advanced paternal age has been linked with de novo pathogenic variants for Apert syndrome. Affected individuals have a 50% chance of passing the pathogenic variant to each child. Prenatal testing for pregnancies at increased risk is possible if the pathogenic variant has been identified in the family.[2,17]

Conclusion

Even though there is no cure for Apert syndrome, many modalities can be done to prevent or treat complications and help the child to grow near normal as possible. Prenatal Tridimensional Sonographic and Magnetic Resonance Imaging at mid-trimester can diagnose Apert syndrome. Careful clinical, ophthalmologic, respiratory, and radiologic monitoring is necessary to treat Apert syndrome patients most appropriately. Surgical treatment requires

a team which includes neuroradiologist, craniofacial surgeon, pediatric surgeon, pediatric anesthetist, plastic surgeons for hand surgery and orthodontist.[17,30]

References

1. Harper JI. Genetics and genodermatoses. In: Champion RH, Burton JL, Burns D, Breathnach SM (editors): Rook/ Wilkinson/ Ebling, Text book of dermatology. 6th ed. Oxford: Black Well Science; 1998:425-6.
2. Mukhopadhyay AK, Mukherjee D. Apert's syndrome. Indian J Dermatol Venereol Leprol 2004;70:105-7.
3. Cohen MM Jr, Kreiborg S. New indirect method for estimating the birth prevalence of the Apert's syndrome. Int J Oral Maxillofac Surg 1992;21:1079.
4. Sohi BK, Sohi AS. Apert's syndrome. Indian J Dermatol Venereol Leprol 1980;46:169-72.
5. Cohen MM Jr, Kreiborg S. An updated pediatric perspective on the Apert syndrome. Am J Dis Child 1993;147:989-93.
6. Wilkie AO, Wall SA. Craniosynostosis- Novel insights into the pathogenesis and treatment. Curr Opin Neurol 1996;9:146-52.
7. Chen L, Li D, Li C, Engel A, Deng CX. Ser250trp substitution in mouse fibroblast growth factor receptor 2 (FGFR2) results in craniosynostosis. Bone 2003;33:169-78.
8. WilkieAO, SlaneySF, OldridgeM, PooleMD, AshworthGJ, HockleyAD, HaywardRD, DavidDJ, PulleynLJ, Rutland P, Apert syndrome results from localized mutations of FGFR2 and is allelic with Crouzon syndrome. Nature genetics. 1995 Feb.
9. Cohen MM Jr, Kreiborg S. A clinical study of the craniofacial features in Apert syndrome. Int J Oral Maxillofac Surg. 1996;25:45–53. [PubMed: 8833300]
10. Cohen MM, Kreiborg S. Cutaneous manifestations of Apert syndrome. Am J Med Genet. 1995;58:94–6. [PubMed: 7573165]
11. Nurko C, Quinones R. Dental and orthodontic management of patients with Apert and Crouzon syndromes. Oral Maxillofac Surg Clin North Am. 2004;16:541–53. [PubMed: 18088753]
12. Dalben GS, et al. Oral findings in patients with Apert syndrome. J Appl Oral Sci. 2006;14:465–9. [PMC free article: PMC4327301] [PubMed: 19089249]
13. Khong JJ, Anderson P, Gray TL, Hammerton M, Selva D, David D. Ophthalmic findings in Apert's syndrome after craniofacial surgery: twenty-nine years' experience. Ophthalmology. 2006b;113:347–52. [PubMed: 16458095]
14. Agochukwu NB, Solomon BD, Muenke M. Hearing loss in syndromic craniosynostoses: otologic manifestations and clinical findings. Int J Pediatr Otorhinolaryngol. 2014;78:2037–47. [PubMed: 25441602]
15. Cohen MM Jr, Kreiborg S. Upper and lower airway compromise in the Apert syndrome. Am J Med Genet. 1992;44:90–3. [PubMed: 1519659]
16. Wenger TL, Dahl J, Bhoj EJ, Rosen A, McDonald-McGinn D, Zackai E, Jacobs I, Heike CL, Hing A, Santani A, Inglis AF, Sie KC, Cunningham M, Perkins J. Tracheal cartilaginous sleeves in children with syndromic craniosynostosis. Genet Med. 2017;19:62–8. [PMC free article: PMC5846326] [PubMed: 27228464]
17. Saritha S, Sumangala, Supriya G, Praveen Kumar M. Apert syndrome (Acrocephalosyndactyly): a case report. Int J Res Med Sci 2013;1:36-40.
18. Mantilla-Capacho JM, Arnaud L, Diaz-Rodriguez M, Barros-Nunez P. Apert syndrome with preaxial polydactyly showing the typical mutation Ser252Trp in the FGFR2 gene. Genet Couns. 2005;16:403–6. [PubMed: 16440883]
19. Breik O, Mahindu A, Moore MH, Molloy CJ, Santoreneos S, David DJ. Central nervous system and cervical spine abnormalities in Apert syndrome. Childs Nerv Syst. 2016;32:833–8. [PubMed: 26861132]
20. McHugh T, Wyers M, King E. MRI characterization of the glenohumeral joint in Apert syndrome. Pediatr Radiol. 2007;37:596–9. [PubMed: 17453189]
21. Tan AP, Mankad K. Apert syndrome: magnetic resonance imaging (MRI) of associated intracranial anomalies. Childs Nerv Syst. 2018;34:205–16. [PubMed: 29198073]
22. Renier D, Arnaud E, Cinalli G, Sebag G, Zerah M, Marchac D. Prognosis for mental function in Apert's syndrome. J Neurosurg. 1996;85:66–72. [PubMed: 8683284]
23. Fernandes MB, Maximino LP, Perosa GB, Abramides DV, Passos-Bueno MR, Yacubian-Fernandes A. Apert and Crouzon syndromes--cognitive development, brain abnormalities, and molecular aspects. Am J Med Genet A. 2016;170:1532–7. [PubMed: 27028366]
24. Pelz L, Unger K, Radke M. Esophageal stenosis in acrocephalosyndactyly type I. Am J Med Genet. 1994;53:91. [PubMed: 7802047]
25. Bissacotti Steglich EM, Steglich RB, Melo MM, de Almeida HL Jr. Extensive acne in Apert syndrome. Int J Dermatol. 2016;55:e596–8. [PubMed: 27428282]
26. David DJ, Anderson P, Flapper W, Syme-Grant J, Santoreneos S, Moore M. Apert syndrome: outcomes from the Australian Craniofacial Unit's Birth to Maturity Management Protocol. J Craniofac Surg. 2016;27:1125–34. [PubMed: 27380568]
27. AzourySC,ReddyS,ShuklaV,Deng CX, Fibroblast Growth Factor Receptor 2 ({i}FGFR2{/i}) Mutation Related Syndromic Craniosynostosis. International journal of biological sciences..2017 : 8.
28. Mathijssen IM, Guideline for Care of Patients With the Diagnoses of Craniosynostosis: Working Group on Craniosynostosis. The Journal of craniofacial surgery. 2015 Sep.
29. WarrenSM,ProctorMR,BartlettSP,BlountJP,BuchmanSR,BurnettW,FearonJA,KeatingR,MuraszkoKM,RogersG F,RubinMS,McCarthy JG, Parameters of care for craniosynostosis: craniofacial and neurologic surgery perspectives. Plastic and reconstructive surgery. 2012 Mar
30. Holten IW, Bourne AJ. The Apert syndrome hand: pathologic anatomy and clinical manifestations. Plast Reconstr Surg 1997;96:1681-7.